



PATIENT

Jamie Carter

SPECIES

Feline

BREED

DSH

SEX

Male Neutered

AGE

3 years

WEIGHT

13.8lbs

INTERPRETED BY

Maggie Machen Lamy,
DVM, DACVIM
(Cardiology)

IMAGING PERFORMED BY

Emily Kalenius, DVM

HOSPITAL NAME

Willamette Veterinary
Hospital

REFERRING VET

Dr. Carter

INVOICE

20777

DATE

8/27/21

PRESENTING CLINICAL SIGNS

History: Grade 4/6 murmur heard on routine exam.
-Abnormal PE/Chem/CBC/UA Results: BP: 202/148, ProBNP 324.

ECHOCARDIOGRAM FINDINGS

2D, m-mode, color flow and doppler imaging is available. The left ventricular wall is moderately hypertrophied. There is a diffusely hyperechoic endocardium consistent with fibrosis and ventricular remodeling. Mild papillary muscle remodeling. The right ventricle is normal. There is no left atrial enlargement present. No right atrial enlargement present. Normal RVOT velocity. Abnormal anterior motion of the mitral valve is present, with a significantly elevated LVOT velocity. The anterior leaflet of the MV is elongated and thickened, consistent with some degree of dysplasia. There is mild to moderate eccentric mitral regurgitation present. No PI. No other valvular leaks noted. There is no pericardial effusion noted. No pleural effusion appreciated. No cardiac tumors.

CARDIAC CHART

FELINE CARDIAC PARAMETERS	BODY WEIGHT (kg)	HR (BPM)	IVSd (cm) (Moise, Pipers)	LVIDd (cm) (Moise, Pipers)	LVWd (cm) (Moise, Pipers)	FS (%)	EF (%)
NORMAL PARAMETER	-----	150-240	0.35-0.55	<2 (mean 1.5)	3.5-0.55	35-67	80-100
PATIENT	6.3	180	0.7	1.16	0.71	42	80
FELINE CARDIAC PARAMETERS	LA/AO (Boon)	LA/AO HEART BASE (Swe) (Abbott)	LA 2D short axis Base view (cm) (Abbott)	LVOT VEL (m/s)	RVOT VEL (m/s)	E max (m/s)	
NORMAL	<1.5	<1.3	<1.2	<1.6	<1.3	<0.9	
PATIENT	1.6	1.2	1.1	3.4	0.6	NM	

**Note: All measurements based upon multi-modal images and methods. An average value is reported.*
Adapted from June Boon, Veterinary Echocardiography, 1998
Abbott J & MacLean H JVIM 2006;20: 111-119, Moise et al. Am J Vet Res 47:1476, 1986. Pipers et al. Am J Vet Res 40:882, 1979.

INTERPRETATION OF THE FINDINGS & FURTHER RECOMMENDATIONS

The presumptive diagnosis and cause of the murmur is mitral valve dysplasia leading to LV hypertrophy and an obstructive LVOT flow pattern. A primary hypertrophic component cannot be ruled out prior to assessing for progression. Regardless, there is no left atrial enlargement indicating the risk of spontaneous CHF and/or a thrombotic event is currently low. No additional issues are identified.

In cases of solely primary MV dysplasia use of atenolol can lead to improvement in the degree of obstruction and hypertrophy. Given today's findings and the young age of the patient, it is reasonable to initiate at this time as below. Monitor at home for any respiratory signs or



PATIENT

Jamie Carter

evidence of blood clot events (neurologic change, paralysis, etc.). A screening BP and T4 are highly recommended every 6-12 months as possible contributing factors.

SPECIES

Feline

Long term prognosis is guarded given the highly variable nature of asymptomatic feline heart disease. Many cats will remain asymptomatic until mid-life or beyond, while others develop CHF within the first years. Close monitoring for response/improvement with atenolol, progression of LA dilation/LVH in the future will help determine long term prognosis.

BREED

DSH

Anesthetic risk is considered mildly elevated, with risk for fluid overload, spontaneous CHF, hypotension, etc. Judicious IV fluid rates are advised to avoid fluid overload. Drugs that stimulate heart rate should be avoided unless clinically necessary (glycopyrrolate, atropine). Avoid ketamine, telazol, acepromazine and dexdomitor.

SEX

Male Neutered

PLAN

AGE

3 years

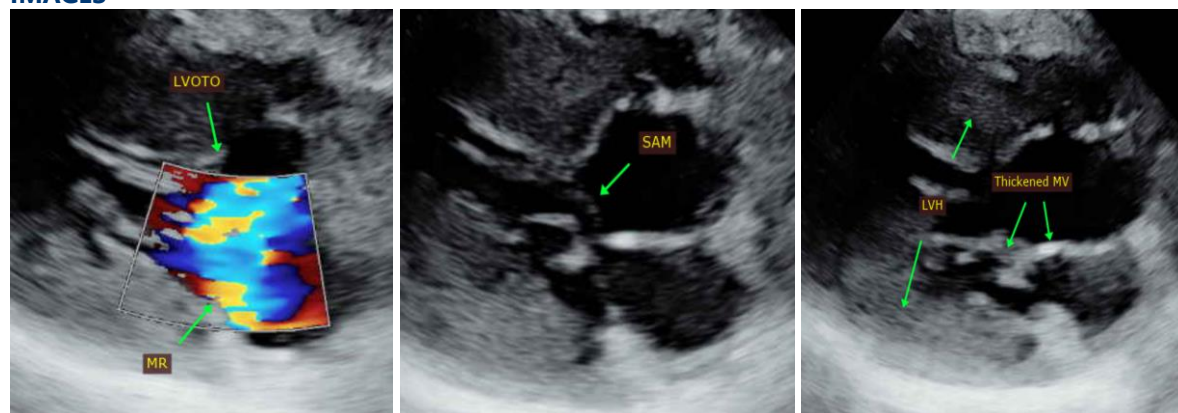
Screening BP/T4 every 6-12 months. Administer titrating dose of atenolol: 25mg tablets; Give ¼ tab once daily. Recheck heart rate in 1-2 weeks with target stressed rate of 140-160bpm 12-24 hours post-administration. Increase as needed until target reached.

WEIGHT

13.8lbs

Recommend recheck echocardiogram in 6 months to assess for progression and response to therapy, sooner if clinical issues arise.

IMAGES



INTERPRETED BY

Maggie Machen Lamy,
DVM, DACVIM
(Cardiology)

IMAGING PERFORMED BY

Emily Kalenius, DVM

HOSPITAL NAME

Willamette Veterinary
Hospital

REFERRING VET

Dr. Carter

The information and recommendations provided are based on the images presented by the referring veterinarian. No evaluation can be communicated regarding pathology that was not visible in the image/video clips provided.

INVOICE

20777

Thank you for this referral. This report was generated using transcription software, and minor dictation errors may be present. If the clinical or image interpretation does not parallel your findings or if I can be of any further assistance, please contact me.

DATE

8/27/21

Maggie Machen Lamy, DVM

Diplomate of the American College of Veterinary Internal Medicine (Cardiology)

info@sonopath.com